

Giant Bladder Diverticulum Presenting with Bilateral Inguinal Pain and Dysuria

● Tuğba Çaviş¹, ● Cansu Bozkurt¹, ● Çetin Kocabıyık², ● Özgür Çınar², ● Selahattin Bedir², ● Kemal Niyazi Arda¹

¹University of Health Sciences Türkiye, Gülhane Training and Research Hospital, Clinic of Radiology, Ankara, Türkiye

²University of Health Sciences Türkiye, Gülhane Training and Research Hospital, Clinic of Urology, Ankara, Türkiye

Abstract

Bladder diverticulum is defined as the herniation of the bladder mucosa and submucosa through the muscular layer. Diverticula are usually asymptomatic and are often diagnosed incidentally. In this case report, we described a giant bladder diverticulum presenting with bilateral inguinal pain, dysuria, and palpable mass in the abdomen. Radiological imaging methods (ultrasonography, computed tomography, magnetic resonance imaging, voiding cystourethrography) were used for further evaluation along with laboratory examinations. After being diagnosed with giant bladder diverticulum, the patient underwent surgery. Postoperative control imaging methods were performed.

Keywords: Giant diverticulum, bladder diverticulum, diverticulectomy, radiology

Introduction

Bladder diverticulum is defined as the herniation of the bladder mucosa and submucosa through the muscular layer.¹ Bladder diverticula often occur secondary to bladder outlet obstruction, which causes high pressure in the bladder.² Diverticula are usually asymptomatic and are often diagnosed incidentally.¹ Symptomatic giant bladder diverticula may present with urinary retention, urinary tract infections, hematuria, abdominal mass, and abdominal pain.³ The incidence of bladder diverticula is 1.7% in children and 1-6% in adults.⁴ In the differential diagnosis of giant bladder diverticula, other abdominal cystic masses such as ovarian cysts, abscess, hematoma, and appendiceal mucocoele should be considered. In this case report, we described a giant bladder diverticulum presenting with bilateral inguinal pain, burning sensation during urination, and palpable mass in the abdomen.

Case Report

A 64-year-old male presented to our center with complaints of a burning sensation during urination, pain in bilateral inguinal regions, and a palpable mass in the abdomen. On physical examination, there was a hard, palpable mass extending from the symphysis pubis to the epigastrium. During the physical examination, it was observed that the patient had tenderness in the suprapubic region. During the initial admission, laboratory data revealed C-reactive protein value of 72.5 mg/L (normal: 0-5 mg/L), hemoglobin value of 11.3 g/dL (normal: 11.9-15.4 g/dL), serum urea value of 49 mg/dL (normal: 18-55 mg/dL), and

serum creatinine value of 0.9 mg/dL (normal: 0.7-1.2 mg/dL). Other laboratory values were within normal range. Radiological imaging methods were used for further evaluation along with laboratory examinations.

Abdominal ultrasonography (US) revealed bilateral grade 3 hydronephrosis, more prominent on the left, a tortuous appearance in the left ureter, a large volume bladder with a double lumen appearance, and a trabeculated appearance on the bladder wall (Figure 1). The connection of both lumens could not be determined by ultrasound. Prostate volume was measured to be approximately 40 cc. Therefore, contrast-enhanced computed tomography (CT) was performed for further evaluation.

CT revealed a giant diverticulum measuring 15 x 9 x 14 cm (craniocaudal x transverse x anteroposterior) associated with the left lateral wall of the bladder. The diverticulum was connected to the bladder lumen by a narrow neck of 13 mm in diameter (Figure 2). The left ureter was observed between the diverticulum and the bladder, and had a tortuous appearance proximal to this level. The diverticulum had no connection with either ureterovesical junction.

With magnetic resonance imaging (MRI) urography a thin-walled diverticulum was observed, while there was a trabeculated appearance on the bladder wall (Figure 3). The narrow neck between the diverticulum and the bladder lumen was well demonstrated with MRI (Figure 3).

Cite this article as: Çaviş T, Bozkurt C, Kocabıyık Ç, Çınar Ö, Bedir S, Arda KN. Giant bladder diverticulum presenting with bilateral inguinal pain and dysuria. Adv Radiol Imaging. 2025;2(1):20-3



Address for Correspondence: Tuğba Çaviş MD, University of Health Sciences Türkiye, Gülhane Training and Research Hospital, Clinic of Radiology, Ankara, Türkiye

E-mail: tugbayayla86@yahoo.com **ORCID ID:** orcid.org/0000-0001-8878-9568

Received: 18.12.2024 **Accepted:** 05.02.2025 **Epub:** 19.03.2025 **Published:** 30.04.2025



Copyright© 2025 The Author. Published by Galenos Publishing House.

This is an open access article under the Creative Commons AttributionNonCommercial 4.0 International (CC BY-NC 4.0) License.

Eventually, voiding cystourethrography (VCUG) was performed to evaluate the discharge of the diverticulum after micturition. A Foley catheter was inserted and contrast material was administered retrogradely. After administration of contrast material, anteroposterior and oblique images were obtained. Afterwards, the catheter was removed, and voiding phase images were obtained. Then, after waiting 30 minutes, the patient was again catheterized and the residual urine in the bladder and diverticulum was evaluated. The catheter was observed in the true bladder lumen on the right. Bladder trabeculation was increased; a giant diverticulum with smooth borders was seen on the left (Figure 4A). In the images taken after voiding, the amount of urine remaining in the bladder decreased significantly, while there was no significant difference in the amount of urine remaining in the diverticulum. In the images taken after re-catheterization, the bladder was completely emptied but a significant residue remained in the diverticulum (Figure 4B).

After being diagnosed with giant bladder diverticulum, the patient was operated on. We operated on our patient using an extravesical approach. This approach allowed identification and dissection of the diverticulum neck (Figure 5). In this patient, the left ureteral orifice

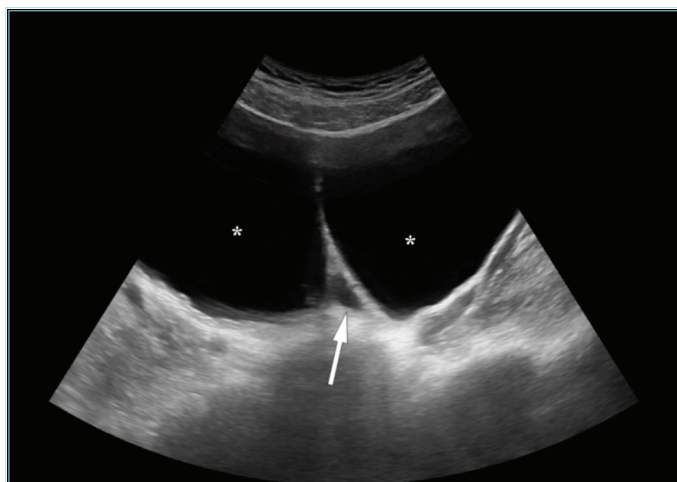


Figure 1. Ultrasonography image demonstrating a large volume bladder with a double lumen appearance (stars) and a dilated left ureter (arrow)

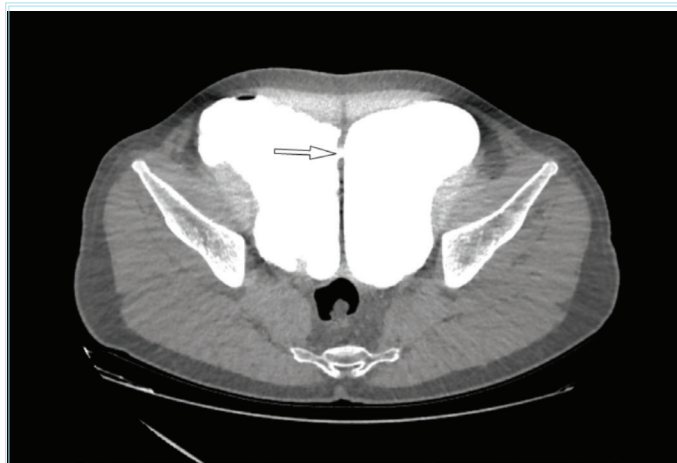


Figure 2. Computed tomography image demonstrating the narrow neck (arrow) between the bladder lumen on the right and the diverticulum on the left

was close to the bladder neck, so a double J catheter was placed in the left ureter intraoperatively. The patient was followed using a urethral catheter for 3 weeks. In the retrograde cystography taken in the third week, it was observed that there was no leakage outside the bladder; consequently, the patient was taken into routine follow-up (Figure 6).

Discussion

Bladder diverticula are divided into two groups: congenital and acquired.⁴ It can also be iatrogenic.⁵ Congenital and acquired bladder diverticula are more common in men.⁶ Congenital bladder diverticulum is thought to be due to a congenital weakness in the bladder wall musculature, and there is usually a single diverticulum.⁷ Acquired diverticula are usually multiple. The most common cause of acquired diverticula is thought to result from increased intravesical pressure.⁸ The most common etiologies of increased intravesical pressure

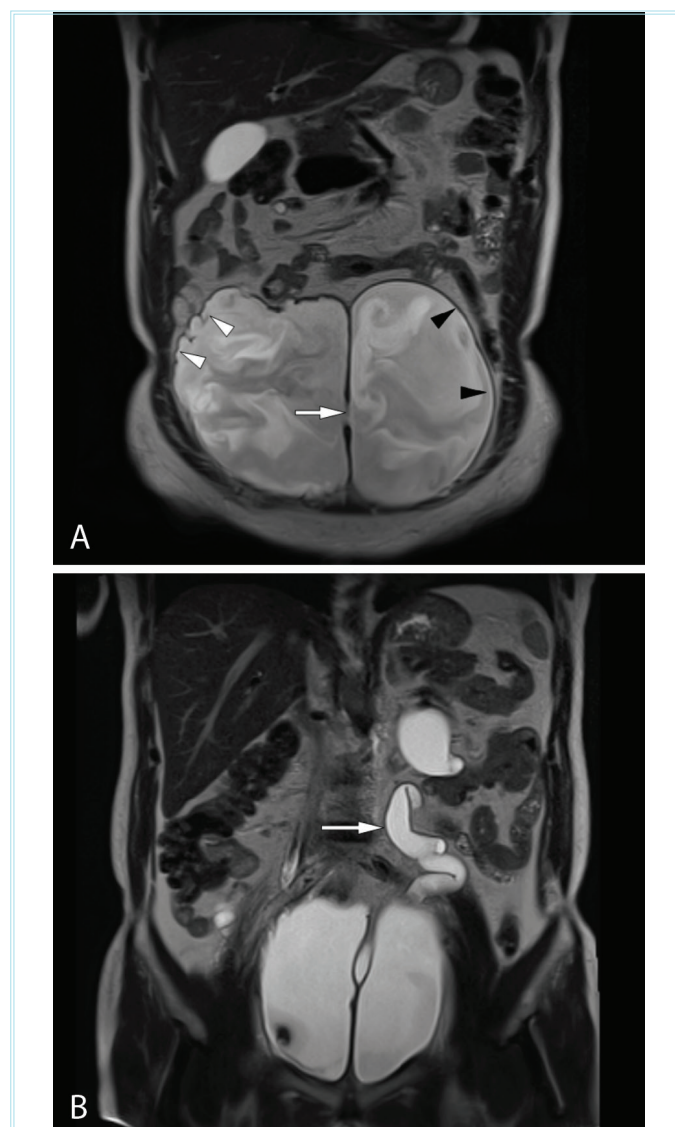


Figure 3. Magnetic resonance imaging (MRI) demonstrating narrow neck (arrow) between the diverticulum and the bladder lumen, trabeculated appearance on the bladder wall (white arrowheads), a thin wall structure of diverticulum (black arrowheads) (A). MRI demonstrating the left ureter between the diverticulum and the bladder, dilated and tortuous proximal to this level (arrow) (B)

include benign prostatic hyperplasia, urethral stricture and voiding dysfunction.¹ Bladder diverticulum is usually asymptomatic and diagnosed incidentally. In those who are symptomatic, the symptoms are often atypical, leading to a delay in diagnosis.³ The most common presentation is recurrent urinary tract infection secondary to residue in the diverticulum. Other reported presentations include acute urinary retention, bladder stones, enuresis, voiding dysfunction, and bladder obstruction.⁹ Our patient presented with bilateral inguinal pain, dysuria, and a palpable mass in the abdomen.

US, CT, MRI, and VCUG can be used to diagnose diverticula. We used all of these imaging methods when diagnosing the condition.

The surgical methods include open or laparoscopic diverticulectomy.¹⁰ We preferred open diverticulectomy in our patient. Diverticulectomy can be performed by an extravesical, intravesical, or combined approach with good results. The basic principle is to dissect close to the wall of the diverticulum, while the bladder muscle defect must be

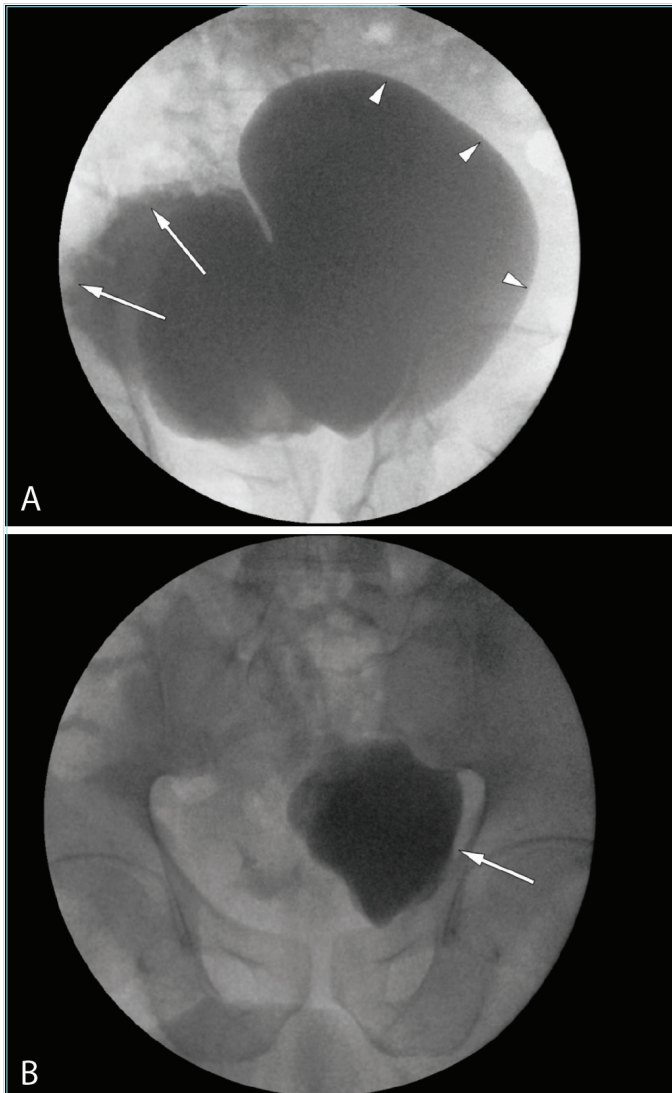


Figure 4. VCUG image demonstrating increased bladder trabeculation (arrows), a giant diverticulum with smooth borders (arrowheads) (A). The image taken after re-catheterization demonstrating completely emptied bladder and significant residue remained in the diverticulum (arrow) (B)

VCUG: Voiding cystourethrography

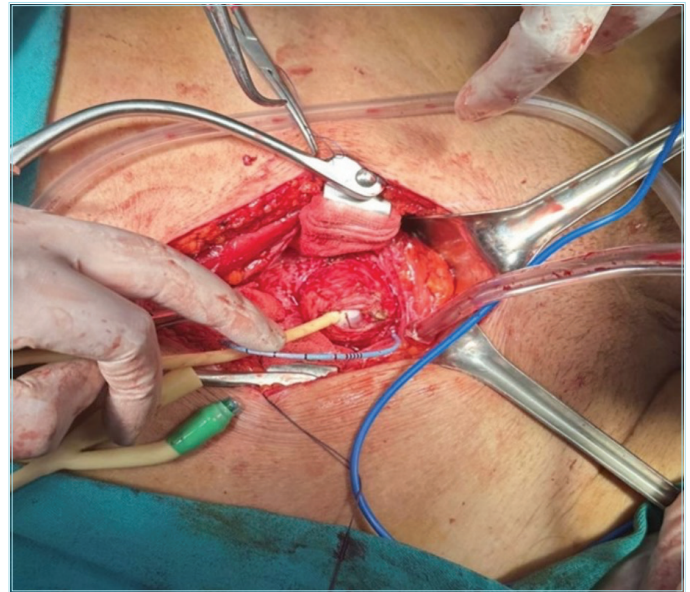


Figure 5. Location of the diverticulum neck

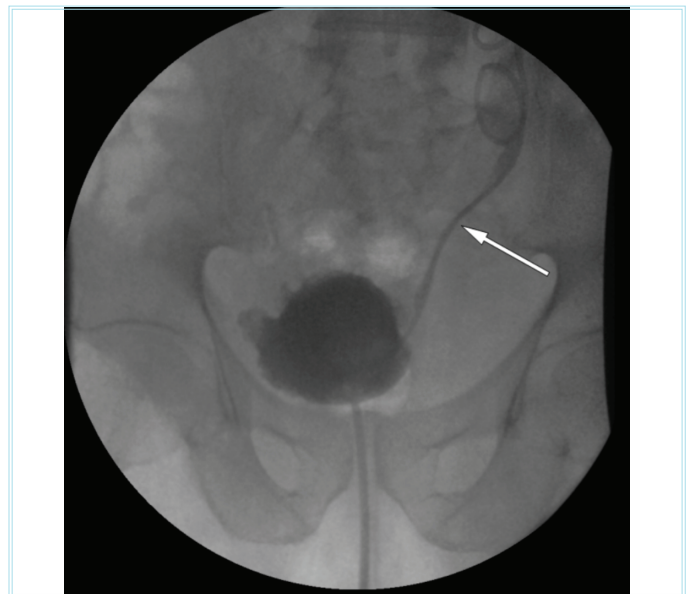


Figure 6. Retrograde cystography demonstrating no leakage outside the bladder. Double J catheter is seen on the left (arrow)

meticulously repaired.⁷ We operated on our patient using an extravesical approach. There were no complications after surgery, and the patient was discharged.

Conclusion

Bladder megadiverticula may be asymptomatic or their findings may be confused with many diseases. Therefore, making the correct diagnosis is crucial in treatment.

Ethics

Informed Consent: Consent form was filled out by all participants.

Footnotes

Authorship Contributions

Surgical and Medical Practices: Ç.K., Ö.Ç., S.B., Concept: K.N.A., Design: T.Ç., Data Collection or Processing: K.N.A., T.Ç., Analysis or Interpretation: K.N.A., T.Ç., Literature Search: K.N.A., T.Ç., Writing: K.N.A., T.Ç., Ç.K., Ö.Ç.

Conflict of Interest: No conflict of interest was declared by the authors.

Financial Disclosure: The authors declared that this study received no financial support.

References

1. Kumar S, Jayant K, Barapatra Y, Rani J, Agrawal S. Giant urinary bladder diverticula presenting as epigastric mass and dyspepsia. *Nephrourol Mon.* 2014;6:e18918.
2. Appeadu-Mensah W, Hesse AA, Yaw MB. Giant bladder diverticulum: a rare cause of bladder outlet obstruction in children. *Afr J Paediatr Surg.* 2012;9:83-7.
3. Sow O, Sarr A, Ze Ondo C, Sine B, Ndiath A, Ndoye AK. Giant bladder diverticulum in a postmenopausal woman: case report and literature review. *Urol Case Rep.* 2021;39:101807.
4. Senel S, Kizilkan Y, Bulut S, Aktas BK. (2020). Giant bladder diverticulum: A case report and review of the literature. *Ann Clin Anal Med.* 2020:1-4.
5. Chia-Yu Chang J, Hsu TF, How CK. Acute urine retention with two giant urinary bladder diverticula. *J Emerg Med.* 2015;48:e39-40.
6. Levard G, Aigrain Y, Ferkadji L, Elghoneimi A, Pichon J, Boureau M. Urinary bladder diverticula and the Ehlers-Danlos syndrome in children. *J Pediatr Surg.* 1989;24:1184-6.
7. Sheldon CA, Essig KA. Congenital bladder diverticulum causing bladder outlet obstruction: case report and review of the literature. *Pediatr Surg Int.* 1994;9:141-3.
8. Silberman M, Jeanmonod R. Bladder diverticulitis: a case report. *Case Rep Emerg Med.* 2011;2011:303498.
9. Jiang S, Ren Q, Wang X, et al. A huge bladder diverticulum in an elderly: A case report. *SAGE Open Med Case Rep.* 2020;8:2050313X20943475.
10. Vaddi S, Pogula V, Devraj R, Sreedhar A. Congenital bladder diverticulum - a rare adult presentation. *J Surg Case Rep.* 2011;2011:8.